

# Presentation, course, and outcome of postneonatal presentations of vein of Galen malformation: a large, single-institution case series

VIGNESH GOPALAN<sup>1</sup>  | ADAM RENNIE<sup>2</sup> | FERGUS ROBERTSON<sup>2</sup> | LAKSHMI KANAGARAJAH<sup>2</sup> | CLAIRE TOOLIS<sup>3</sup> | SANJAY BHATE<sup>3</sup> | VIJEYA GANESAN<sup>1,3</sup>

**1** Developmental Neurosciences, UCL Great Ormond Street Institute of Child Health, London; **2** Radiology Department, Great Ormond Street Hospital for Children, NHS Foundation Trust, London; **3** Neurology Department, Great Ormond Street Hospital for Children, NHS Foundation Trust, London, UK.

Correspondence to Vignesh Gopalan at 156 Portland Crescent, London HA7 1LU, UK. E-mail: vignesh.gopalan.13@ucl.ac.uk

## PUBLICATION DATA

Accepted for publication 6th December 2017.

Published online

## ABBREVIATIONS

RRQ	Recovery and Recurrence Questionnaire
VGM	Vein of Galen malformation

**AIM** To describe presentation, clinical course, and outcome in postneonatal presentations of vein of Galen malformation (VGM).

**METHOD** Children older than 28 days presenting with VGM (from 2006–2016) were included. Notes/scans were reviewed. Outcome was dichotomized into ‘good’ or ‘poor’ using the Recovery and Recurrence Questionnaire. Logistic regression was performed to explore relationships between clinico-radiological features and outcome.

**RESULTS** Thirty-one children (18 males, 13 females) were included, presenting at a median age of 9.6 months (range 1.2mo–11y 7mo), most commonly with macrocrania ( $n=24$ ) and prominent facial veins ( $n=9$ ). Seven had evidence of cardiac failure. VGM morphology was choroidal in 19. Hydrocephalus ( $n=24$ ) and loss of white matter volume ( $n=15$ ) were the most common imaging abnormalities. Twenty-nine patients underwent glue embolization (median two per child). Angiographic shunt closure was achieved in 21 out of 28 survivors. Three children died of intracranial haemorrhage (1y, 6y, and 30d after embolization). Ten patients underwent neurosurgical procedures; to treat haemorrhage in four, and hydrocephalus in the rest. Outcome was categorized as good in 20 out of 28 survivors, but this was not predictable on the basis of the variables listed above.

**INTERPRETATION** Postneonatal presenting VGM has distinctive clinico-radiological features, attributable to venous hypertension. Endovascular treatment is associated with good outcomes, but more specific prognostic prediction was not possible within this cohort.

Vein of Galen malformation (VGM) is a rare cerebral intracranial vascular malformation developing between primitive choroidal arteries and the median prosencephalic vein (the precursor of the vein of Galen) between 6 weeks and 11 weeks of gestation.<sup>1</sup> VGM contrasts with vein of Galen aneurysmal dilatation, where the vein of Galen itself is dilated by draining a high-flow arteriovenous shunt elsewhere within the brain. Classification of VGM was initially predominantly based on angiographic features,<sup>2</sup> but a more recent classification reflects increasing recognition of the relevance of the mode and age of presentation (specifically whether the child is older than 5mo, when there is potential for alternative cortical venous drainage through the cavernous sinus).<sup>3</sup>

Most patients present in the newborn period with circulatory overload and multiorgan failure secondary to the effects of the large intracranial shunt. Historically, studies reported high mortality rates and significant morbidity in survivors.<sup>2,4</sup> However, with the advent of endovascular treatments, VGM has become a treatable and potentially curable condition in

many cases. Intervention is high risk and selection of patients in whom the risk:benefit equation favours treatment remains a challenge. Most literature has focussed on neonates but, in the context of a nationally commissioned service managing patients presenting with VGM in the UK since 2006, our clinical experience has been that the clinical manifestations and underlying pathophysiology were distinct in older children. Here we aim to describe such patients presenting to us between 2006 and 2016.

## METHOD

Since 2006 we have been one of two nationally commissioned centres in the UK treating all cases of VGM. Patients are managed in a standardized manner by a multi-disciplinary team, with clinical evaluation and both cross-sectional brain imaging comprising magnetic resonance imaging (MRI) and diagnostic catheter angiography performed at presentation. This allows a planned, and usually staged, approach to endovascular treatments, which include transarterial glue injection, insertion of coils, or

**Table I:** Analysis of radiological imaging

	Frequency on initial imaging	Frequency on final imaging
Cross-sectional imaging		
Brain injury	21	23
Hydrocephalus	24	21
Angiography		
Venous outflow impairment	16	19
Venous congestion	7	19
Residual shunt		10

transvenous treatments, although the first of these is by far the most common treatment administered. Patients presenting with hydrocephalus are evaluated for, and undergo endovascular treatment of, the shunt in the first instance. Cerebrospinal fluid diversion is only undertaken as a secondary measure, when control of intracranial pressure is not achieved by embolization.

Patients presenting to us between 1st January 2006 and 31st December 2016 after 28 days of age, with a diagnosis of VGM, were eligible for inclusion. Clinical data (demographics, presenting features, information about the treatment course and any associated complications) were extracted from case records. Brain imaging and cerebral angiograms were reviewed by AR/FR/LK and categorized as summarized in Table I. Initial and most recent imaging studies were evaluated and compared.

Outcome was evaluated from case notes using the Recovery and Recurrence Questionnaire (RRQ), a measure validated for scoring outcomes from case notes in paediatric vascular disorders.<sup>5</sup> Five domains are assessed on the RRQ: (1) right and (2) left sensorimotor function, (3) verbal expression, (4) language comprehension, and (5) cognition and behaviour. A score of zero indicates no impairment, and a maximal score of two indicates severe impairment with limitation of function. Outcome is then dichotomized into 'good' and 'poor' groups; a 'good' outcome is a score of  $\leq 0.5$  in every category, indicating no significant neurodevelopmental impairment in any of the five domains. A score of 1 or more in any category meant that the child was assigned to have 'poor' outcome.

### Ethical approval

The hospital audit department confirmed that ethical approval was not required for retrospective evaluation of these clinical data and the project was registered with them as a clinical service evaluation.

### Statistical analysis

On the basis of descriptive statistical analysis of the data collected, we used a univariable logistic regression model to explore the relationship between specific clinico-radiological features (presence of brain injury, presence of abnormal venous outflow, and presence of hydrocephalus) and outcome. With consideration of the parameters detailed by

### What this paper adds

- Clinical and radiological features in older children with vein of Galen malformation relate to venous hypertension.
- Outcome is good in most cases with endovascular therapy.
- Mortality is low but is related to intracranial haemorrhage.

Peduzzi et al.,<sup>6</sup> we intended to enter any significant predictors into a multivariable model.

### Review of the literature

We performed a literature search using PubMed, EMBASE, and the Cochrane Library using the search terms 'vein of Galen malformation', 'VGM', 'infant', and 'post-neonatal' in various combinations. References found within the articles were also assessed. A total of 29 articles describing 556 cases of postneonatally presenting VGM since 1964 were found. We extracted information about clinical features at presentation, treatment course, and outcomes for comparison with our own findings. Most articles described small cohorts or isolated cases of postneonatally presenting VGM, with most cases in our review coming from one centre, the Bicêtre Hospital in Paris, France, who published a series of 193 patients.<sup>7</sup>

Description of presenting features was sparse in most articles, and the age of the child at presentation was not reported with regard to their presenting features. Treatment methods included transarterial or transvenous glue embolization, or insertion of coils, with the former being the most common. Data on adjunctive procedures and complications were not consistently reported so this was not examined in our review. Outcome measures also varied, with some studies using radiological elimination of the shunt<sup>8,9</sup> and others basing outcome on postintervention survival rates.<sup>10,11</sup> Postoperative neurodevelopmental sequelae were reported by some centres, most comprehensively detailed by Fullerton et al.<sup>12</sup> who described six cases of postneonatal VGM, five of whom (83%) were intact at follow-up, with the remaining child reported to have severe abnormalities on neurological examination and significant developmental delay. Reports from other centres<sup>7,13,14</sup> lacked long-term follow-up and did not differentiate between the degree of neurological deficit, instead broadly classifying children as 'impaired'.

## RESULTS

### Demographics

Thirty-one children (18 males, 13 females) were included, of whom 28 were still alive. Median age at presentation was 9.6 months (range 1.2mo–11y 7mo), with most children presenting in the first year of life. The median age of surviving children was 7 years 5 months (range 1y 1mo–15y 10mo).

Macrocrania was the most common clinical presentation ( $n=24$ ) with nine children having a head circumference larger than the 99.6th centile for their age. Other clinical features (not mutually exclusive) included prominence of facial veins noted by parents ( $n=9$ ), developmental delay ( $n=8$ ), focal neurological deficits ( $n=8$ ), heart failure ( $n=7$ ),

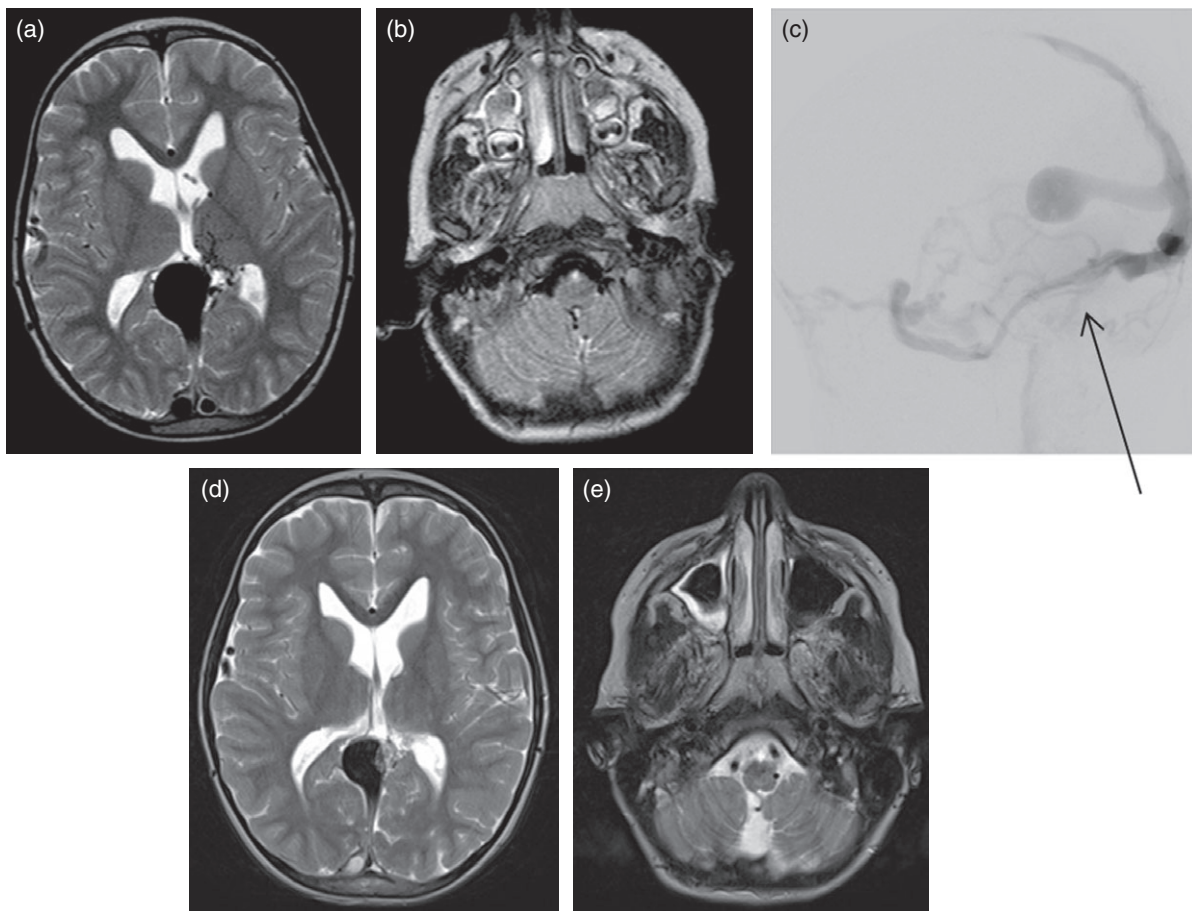
seizures ( $n=5$ ), and headache ( $n=5$ ). Of note, headache and prominence of facial veins were only observed in children presenting after the age of 2 years.

### Radiological findings

Cross-sectional brain imaging (computed tomography and/or MRI) and cerebral angiography were reviewed in all patients (Fig. 1). The results are summarized in Table I. The most common brain abnormalities were hydrocephalus and loss of white matter bulk; these were difficult to distinguish and a clinical judgement was made by the three neuroradiologists about the appropriate diagnostic label in individual cases. Even taking into account head circumference, it was often difficult to distinguish between these, but the relevant observation is that the white matter bears the brunt of the injury in these patients. Accrual of brain injury after initial presentation was rare in the survivors, occurring in only two cases.

Angiographic features were dominated by the impairment of venous drainage, often associated with stenosis of the venous outflow channels at the skull base. In those patients with symptomatic venous congestion, the aim of the embolization procedures was to reduce the shunt and improve cerebral venous drainage. A complication of embolization was venous escape of the embolic material, which was reflected in the rise in the number of children with venous outflow obstruction.

Cavernous sinus capture (drainage of cortical veins via the cavernous sinus) was also assessed from the first available cerebral angiogram. The results are displayed in Table II as to whether the child was older than 5 months, as this is when the alternative pathways through the cavernous sinus are thought to have formed. There was no significant difference in the rate of cavernous sinus capture between patients who had good outcomes compared with those with poor outcomes ( $\chi^2$  test,  $p=0.600$ ).



**Figure 1:** Axial T2-weighted images (a) through the vein of Galen malformation sac and (b) at the level of the foramen magnum. The cerebellar tonsils are prolapsed inferiorly. The lateral ventricles are prominent. Numerous arterial feeders are noted, with most passing through the thalamus. (c) Left vertebral artery angiogram demonstrating vein of Galen malformation venous sac. There is occlusion of the sigmoid sinus (arrow), with multiple venous collaterals, including those through the superior petrosal sinus. There is venous congestion of the cerebellum. (d, e) Axial T2-weighted images after partial endovascular treatment. There are fewer arterial feeders and there is some embolic material in the sac; however, the vein of Galen malformation remains patent. The tonsils are no longer prolapsed. The ventricles remain prominent.

**Table II:** Presence of cavernous sinus capture in relation to outcome

Age at earliest angiography (mo)	Good outcome (n of children with cavernous capture)	Poor outcome (n of children with cavernous capture)
<5	8 (6)	2 (2)
>5	10 (9)	6 (4)
Deceased	3	
No angiogram available	2	

Ten patients had a residual arteriovenous shunt on their most recent angiogram.

### Treatment course and complications

One patient had spontaneous collapse of the VGM sac and thus did not require any endovascular treatment. Another had not had embolization performed. These patients were therefore both excluded from the analysis in this section.

The remaining 29 children underwent a total of 68 embolization procedures. Two procedures were coil embolizations, the rest were glue embolizations. A median of two embolizations were performed per child (range 0–6 embolizations), with the median time to embolization being 4 days from presentation (range 0–322d).

Nineteen embolizations in 14 patients were associated with intraprocedural complications. Escape of glue into the venous sinuses was the most common of these ( $n=12$ ), associated with venous sinus thrombosis in four cases. All four underwent endovascular interventions (stenting/thrombolysis) to resolve this, leaving no permanent neurological sequelae. Other complications included iliac artery occlusion ( $n=1$ ) and intraventricular haemorrhage ( $n=1$ ).

Neurosurgical intervention (third ventriculostomy/external ventricular drainage/ventriculo-peritoneal shunt insertion) was required in 10 children. Four procedures were done to resolve acute peri-procedural intracranial haemorrhage. Eight cerebrospinal fluid drainage procedures were undertaken, two of which were undertaken as emergencies.

### Outcome

Median length of follow-up was 1 year 11 months (range 2y 5mo–6y 2mo). Three patients died during their treatment course, and have been excluded from the analysis

**Table IV:** Review of the literature

Presenting feature	Frequency	Outcome		
		Treated (n=456)	Untreated (n=44)	Outcomes in 56 cases were unknown
Hydrocephalus	25	Normal	296	
Macrocrania	14	Impaired	93	
Cardiac failure	14	Dead	67	
Cranial bruit	10	Normal	14	
Seizures	9	Impaired	15	
Haemorrhage	4	Dead	15	
Developmental delay	3			
Prominent facial veins	3			
Focal neurological deficits	2			
Headache	2			

below. Death occurred 1 day, 6 days, and 30 days after their most recent embolizations, which had been otherwise uncomplicated, as a result of catastrophic spontaneous intracranial haemorrhage. One of these patients had an emergency extraventricular drain placed to relieve the intracranial pressure, but died shortly after because of brain herniation.

Of the remaining 28 patients, a ‘good’ outcome was seen in 20; it is notable that although two-thirds of the children had abnormal scans, outcome was categorized as ‘good’ in a similar proportion. The most common domains of concern in the RRQ related to language, cognition, or behaviour. In contrast, only one child exhibited motor impairment.

### Statistical analysis

Significance level was set at an arbitrary threshold of 5%, and was two-tailed. The results of the univariable regressions (Table III) showed that the clinico-radiological parameters assessed had no significant effect on outcome. We did not perform a further multivariable regression analysis.

### Review of the literature

Out of the 556 cases extracted, only 86 (15%) offered description of presenting features (Table IV), reflecting the paucity in the literature describing presentations of post-neonatal VGM. Hydrocephalus, macrocrania, and cardiac failure were the most common presentations. Four

**Table III:** Univariable regression analysis

Parameter	Good outcomes (n=20)	Poor outcomes (n=8)	Odds ratio	95% confidence intervals		p
				Lower	Upper	
Presence of brain injury (first MRI)	12	6	0.6	0.09	3.90	0.600
Presence of brain injury (final MRI)	15	6	1.2	0.18	8.24	0.860
Venous outflow impairment (first angiography)	11	3	1.6	0.29	9.25	0.580
Venous outflow impairment (final angiography)	12	5	0.69	0.10	4.52	0.700
Presence of hydrocephalus	15	6	1.2	0.18	8.24	0.850

MRI, magnetic resonance imaging.



hundred and fifty-six children had undergone treatment for their VGM, with 296 (65%) categorized as having a 'normal' outcome by the measures specified by the authors. The death rate in the review population was lower than 15%. This may be a result of reporting bias between centres, or because of the less severe presentation of infants compared with neonates. Thus, broadly, our results were comparable in terms of clinical presentation but perhaps more positive in terms of outcome.

## DISCUSSION

There are encouraging outcomes in most children presenting with VGM beyond the neonatal period, with two-thirds of our population showing no or mild neurological impairment at follow-up. The lack of prospectively collected outcome data and the relatively small sample size limit our ability to comment on predictors of outcome. Owing to the breadth of the categories on the RRQ, subtle deficits in functional status may have not been picked up, and the ability of children classed as having a 'good' outcome may have been overestimated in some cases. Lack of a power calculation (difficult owing to the rarity of postnatal presentation of VGM) meant that a non-significant finding may in fact have been true.

The most frequent presentation of VGM is in neonates with brain ischaemia and multiorgan dysfunction secondary to hypoperfusion: a truly life-threatening situation with a high rate of death and impairment even with treatment. In contrast, the 'hydrovenous' features that are prevalent in older children are far more insidious, and relate both to abnormally high volumes of blood being shunted into the venous system and, often, to an acquired outflow obstruction at the level of the jugular bulb. The latter is thought to be, at least in part, secondary to the chronic effects of venous hypertension and is challenging to treat or reverse, as stenting is rarely successful in any sustained way. Although alternative routes of cortical venous drainage may afford a degree of protection against venous hypertension, we were not able to demonstrate a difference in outcome according to whether there was cavernous sinus capture. Hydrocephalus in this context is thought to relate both to impairment to cerebrospinal fluid resorption in the high pressure venous system, but also to direct compression of the cerebral aqueduct by the VGM sac.<sup>15</sup> Of note, parents tell us that the significance of presenting features (macrocrania, prominent facial veins) often goes unrecognized for a long time, even by medical professionals. We had a minority of cases presenting with developmental

arrest; however, none of these were associated with the catastrophic so-called 'melting brain syndrome' that indicates critically decompensated acute venous hypertension. The urgency of this presentation cannot be overemphasized and thus developmental standstill or seizures in VGM should be treated as medical emergencies.

Loss of white matter volume was the most common brain injury in this cohort; surprisingly, it did not cause impairment of motor function as assessed on the RRQ. However, study of a similar cohort of 28 children at the Royal Hospital for Sick Children in Glasgow, UK, using more detailed and face-to-face assessments, reported motor delay as the most significant finding (McArthur I, Yeo TH, and Bhattacharya J, personal communication 2015), although, of note, these often coexisted with delays in other aspects development. Potential explanations for this are that the RRQ is relatively crude, or that the children in the Glasgow study had a more global pattern of impairment. Historically, outcome in the treatment of VGM has been measured by mortality rates and shunt elimination; however, in an era where endovascular embolization has significantly lowered death rates, and with angiographic exclusion not necessarily being a good predictor of outcome,<sup>2,16</sup> there is an argument for using neurodevelopmental morbidity and functional status at follow-up as potential outcome measures, and for prospective and serial neurodevelopmental assessment to form an integral part of our care pathway.

Our results add to a growing body of evidence of improved outcomes in the era of endovascular treatment for VGM: a good outcome in non-neonates is generally seen despite a high rate of abnormal scans at presentation. Analysis of clinical and radiological features contrasts the importance of venous hypertension and outflow obstruction in this group with those of arteriovenous shunting and circulatory failure in neonates. Currently the treatments and approaches in both groups are similar, but these data and the literature review suggest that these should be more targeted to the physiological dysfunction in specific cases. Although timing of intervention and the specific approach to blocking the arteriovenous shunt can be tailored, technical limitations to strategies to relieve venous outflow obstruction continue to be a challenge in this group.

## ACKNOWLEDGEMENTS

The authors have stated that they had no interests that might be perceived as posing a conflict or bias.

## REFERENCES

1. Illner A. Vein of Galen Aneurysmal Malformation. In: Barkovich AJ, editor. *Diagnostic Imaging: Paediatric Neuroradiology*. Salt Lake City, UT: Amirsys, 2007 (Part I-7): 30–33.
2. Lasjaunias PL, Chng SM, Sachet M, Alvarez H, Rodesch G, Garcia-Monaco R. The management of vein of Galen aneurysmal malformations. *Neurosurgery* 2006; **59** (Suppl. 5): S184–94.
3. Mortazavi MM, Griessenauer CJ, Foreman P, et al. Vein of Galen aneurysmal malformations: critical analysis of the literature with proposal of a new classification system. *J Neurosurg Pediatr* 2013; **12**: 293–306.
4. Johnston IH, Whittle IR, Besser M, Morgan MK. Vein of Galen malformation: diagnosis and management. *Neurosurgery* 1987; **20**: 747–58.
5. Lo WD, Ichord RN, Dowling MM, et al. The Pediatric Stroke Recurrence and Recovery Questionnaire: validation in a prospective cohort. *Neurology* 2012; **79**: 864–70.

6. Peduzzi P, Concato J, Kemper E, Holford TR, Feinstein AR. A simulation study of the number of events per variable in logistic regression analysis. *J Clin Epidemiol* 1996; **49**: 1373–9.
7. Lasjaunias PL. Brain and spine AVMs, vein of Galen malformation. Treatments and embryological considerations. *Interv Neuroradiol* 2003; **9**: 263–72.
8. Lylyk P, Viñuela F, Dion JE, et al. Therapeutic alternatives for vein of Galen vascular malformations. *J Neurosurg* 1993; **78**: 438–45.
9. Karanam LS, Baddam SR, Joseph S. Endovascular management of vein of Galen aneurysm malformation: a series of two case reports. *J Pediatr Neurosci* 2011; **6**: 32–5.
10. Diebler C, Dulac O, Renier D, Ernest C, Lalande G. Aneurysms of the vein of Galen in infants aged 2 to 15 months. Diagnosis and natural evolution. *Neuroradiology* 1981; **21**: 185–97.
11. Li AH, Armstrong D, terBrugge KG. Endovascular treatment of vein of Galen aneurysmal malformation: management strategy and 21-year experience in Toronto. *J Neurosurg Pediatr* 2011; **7**: 3–10.
12. Fullerton HJ, Aminoff AR, Ferriero DM, Gupta N, Dowd CF. Neurodevelopmental outcome after endovascular treatment of vein of Galen malformations. *Neurology* 2003; **61**: 1386–90.
13. Hassan T, Nassar M, Elghandour M. Vein of Galen aneurysms: presentation and endovascular management. *Pediatr Neurosurg* 2010; **46**: 427–34.
14. Moon JH, Cho WS, Kang HS, Kim JE, Lee SJ, Han MH. Vein of Galen aneurysmal malformation: endovascular management of 6 cases in a single institute. *J Korean Neurosurg Soc* 2011; **50**: 191–4.
15. Meila D, Grieb D, Melber K, et al. Hydrocephalus in vein of Galen malformation: etiologies and therapeutic management implications. *Acta Neurochir (Wien)* 2016; **158**: 1279–84.
16. Jones BV, Ball WS, Tomsick TA, Millard J, Crone KR. Vein of Galen aneurysmal malformation: diagnosis and treatment of 13 children with extended clinical follow-up. *AJNR Am J Neuroradiol* 2002; **23**: 1717–24.